



ELSEVIER



BRITISH
Journal of
Oral and
Maxillofacial
Surgery

www.bjoms.com

TECHNICAL NOTE

Reduction of a chronic bilateral temporomandibular joint dislocation with intermaxillary fixation and botulinum toxin A

Peter Aquilina*, Richard Vickers, Geoffrey McKellar

Department of Oral and Maxillofacial Surgery, Westmead Hospital, Sydney, Australia

Accepted 17 January 2004

KEYWORDS

IMF;
Botulinum;
Hypercholesterolaemia

Summary A 71-year-old man was referred to the Department of Oral and Maxillofacial Surgery at Westmead Hospital for investigation of limited jaw movement and facial pain after a cerebrovascular event eight weeks previously. He was found to have bilateral dislocations of the temporomandibular joints (TMJ) and was successfully treated with a combination of intermaxillary fixation (IMF) screws and botulinum toxin A.

© 2004 The British Association of Oral and Maxillofacial Surgeons. Published by Elsevier Ltd. All rights reserved.

Case report

A 71-year-old man was admitted to Westmead Hospital having had a left frontoparietal infarct at home. He had a right facial nerve palsy without frontal sparing, a dense right hemiparesis, a decreased gag reflex on the right side, and an expressive dysphasia. He had a background of ischaemic heart disease, chronic atrial fibrillation, and hypercholesterolaemia. A carotid endarterectomy 3 years previously had been complicated by an intraoperative cerebrovascular event. A pacemaker had been inserted 3 years previously. On admission he was taking sotalol 160 mg twice daily and nitrazepam 5 mg at night.

He was managed conservatively and made good progress except for the continuing complaint of limited movement of the jaws and facial pain.

Eight weeks after admission, he was referred to the Department of Oral and Maxillofacial surgery for investigation.

On examination he had a right facial droop, right hemiparesis, and an expressive dysphasia. He had an open lock of his jaw with associated pain in the left and right temporomandibular joint (TMJ). His temporalis, masseter, and lateral pterygoid muscles were tender to palpation bilaterally. He was edentulous in his maxillary arch and had anterior mandibular dentition. An orthopantomogram and views of the TMJ's confirmed the clinical diagnosis of bilateral dislocation.

The next day his dislocated jaw was reduced under general anaesthesia with muscle paralysis. Four 15 mm × 2 mm titanium screws (Synthes) were placed into his maxillae and mandible so that heavy elastics could be applied in a class III configuration (Fig. 1). The holes were drilled directly through the soft tissue at the junction of the free and attached mucosa under copious irrigation with sterile saline and with careful attention paid to the location of the adjacent tooth roots. His mandibular reduction

*Corresponding author. Present address: 20 Lamrock Avenue, Five Dock New South Wales 2046 Sydney, Australia. Tel.: +61-2-97052766.

E-mail address: paquilin@bigpond.com (P. Aquilina).

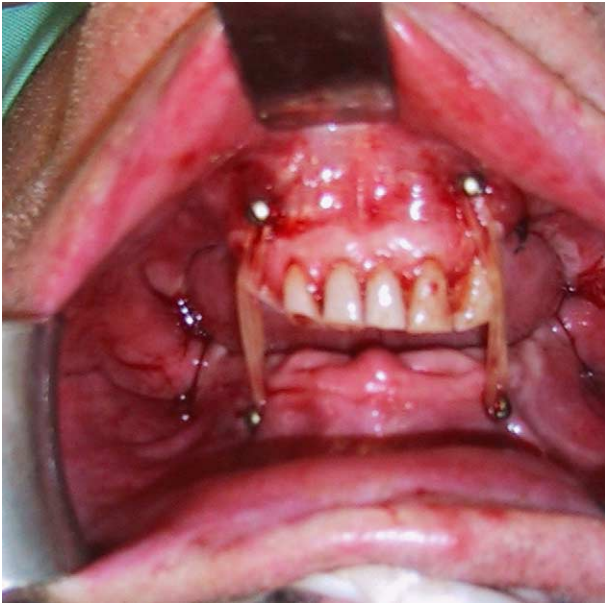


Figure 1 Photograph illustrating the placement of four screws and elastic IMF provided by orthodontic elastics.

was maintained with elastic intermaxillary fixation (IMF). Bupivacaine 0.5% with adrenaline 1/200,000 (Marcaine) 20 ml were infiltrated bilaterally into his masseter, temporalis, medial and lateral pterygoid muscles before extubation, and operating time was less than 15 min.

Postoperatively he had good pain relief and well-controlled mandibular movements, though there was some residual pain on opening. Because of the duration of his dislocation, and to prevent further dislocations, we decided to reduce the muscular activity of his lateral pterygoid muscles and the anterior portion of his temporalis muscles bilaterally.

On the third day following the reduction of his dislocated jaw, botulinum toxin A (Botox, Allergan) was injected under electromyographic control into both his lateral pterygoid muscles and into the anterior fibres of his left and right temporalis muscles. The lateral pterygoid muscles were injected intraorally (30 mouse units) and extraorally through the sigmoid notch (30 mouse units). This allowed 60 mouse units to be delivered into multiple points of the muscle. A further 20 units was injected into the anterior fibres of the temporalis muscle bilaterally, making a total dose of 80 mouse units on each side.

After treatment with botulinum toxin A, he had further relief of pain and unimpaired mandibular range of movement.

He was reviewed regularly and had no recurrence of his mandibular dislocation. His IMF screws were removed two weeks after reduction of the dislocations, without local anaesthetic, and there was no recurrence. Six weeks later he had good range of movement and no complaints of pain in the TMJ.

Discussion

Protracted dislocation of the TMJ after a cerebrovascular event is uncommon and to our knowledge has been reported only once previously.¹ Treatment of such a dislocation with botulinum toxin A has been reported previously,^{2,3} but both these papers concerned patients with recurrent dislocations rather than a single long episode of dislocation.

Botulinum toxin chemically denervates muscles by inhibiting the release of acetylcholine from motor neurones.^{4,5} The area of flaccidity produced may be larger than the area of muscle denervated as a result of postulated paralysis of gamma motor neurones, so the output of the muscle spindles is reduced leading to reduced muscular contraction at adjacent sites within the injected muscle.⁴

Relaxation of treated muscle begins within a few days and lasts for about three months.³ In our patient we maintained the reduction with elastic IMF for two weeks, to allow the botulinum toxin to take effect.

The surgical and anaesthetic time was short, which minimised the risk of anaesthetic complications in a sick patient. This technique may also be applied to a broad range of neuromuscular disorders that cause dislocation of the mandible.

References

- Collins DR, Hogan J, O'Neill D. Temporomandibular dislocation in association with stroke. *Ir Med J* 1999;92:6.
- Daelen B, Thorwith V, Koch A. Treatment of recurrent dislocation of the temporomandibular joint with type A botulinum toxin. *Int J Oral Maxillofac Surg* 1997;26:358–460.
- Moore AP, Wood GD. Medical treatment of recurrent temporomandibular joint dislocation using botulinum toxin A. *Br Dent J* 1997;183:415–7.
- O'Day J. Use of botulinum toxin in neuro-ophthalmology. *Curr Opin Ophthalmol* 2001;12:419–22.
- Allergan Australia Product Information, 77 Ridge Street Gordon, NSW 2072. Therapeutic goods administration approval, 2002 Mar 19.